A companion to medical studies

IN THREE VOLUMES

Volume 3

Medicine, surgery, systemic pathology, obstetrics, psychiatry, paediatrics and community medicine

EDITORS-IN-CHIEF

R. PASSMORE

J. S. ROBSON

Part 2

250119943

BLACKWELL SCIENTIFIC PUBLICATIONS

OXFORD LONDON EDINBURGH MELBOURNE

Source: https://www.industrydocuments.ucsf.edu/docs/pmbj0000

PRIVILEGED & CONFIDENTIAL

32.18 *Diseases of the ear, nose and throat*

DISEASES OF THE NASOPHARYNX

Adenoids

Adenoids is the term used for the nasopharyngeal tonsils, when they become hypertrophied.

CLINICAL FEATURES

Some degree of enlargement of the nasopharyngeal tonsils is normal before puberty and if small, adenoids give rise to no symptoms. When larger, they lead to nasal obstruction either by their size or by producing a chronic rhinitis. As a result of the obstruction, there is mouth breathing, snoring and a toneless voice and in marked cases an 'adenoid facies'. This is recognized by the narrow pinched nares often with mucoid nasal discharge, a high arched palate with crowded teeth, mouth breathing and often a vacant expression. There is doubt as to whether the maldevelopment of the upper jaw is due to adenoids, but the adenoid facies is very characteristic. The nasal obstruction frequently causes sinusitis when the discharge becomes purulent.

A further effect of adenoids is on the function of the auditory tube, causing indrawing of the drums and

25011994HO

Source: https://www.industrydocuments.ucsf.edu/docs/pmbj0000

deafness which may be persistent or intermittent. Fluid may collect in the middle ear and recurring attacks of otitis media with or without otorrhoea are common.

DIAGNOSIS

Adenoids are best diagnosed by posterior rhinoscopy which can often be performed in quite young children. Often, however, the diagnosis has to be made from the other clinical findings, particularly where there is hypertrophy of the palatine tonsils. A lateral radiograph of the nasopharynx may indicate the pressure of adenoids and sometimes it is necessary to palpate the nasopharynx under general anaesthesia before a definite diagnosis can be made.

TREATMENT

In general, where adenoids are the cause of persistent symptoms, they should be removed with a curette. This is done under general anaesthesia, frequently in combination with tonsillectomy. Care should be taken in recommending this operation where there is any deficiency of the palate, e.g. after cleft palate operations or in a congenitally short palate where removal of the adenoids may lead to inadequate closure of the nasopharyngeal isthmus.

Tumours of the nasopharynx

BENIGN TUMOURS

The commonest benign tumour is an angiofibroma, occurring in boys between 10 and 25 years of age. The tumour grows from the region of the base of the sphenoid, or from the lateral or anterior wall of the nasopharynx. It is basically a haemangioma but there is a variable and often abundant intervascular stroma of fibroblastic fibrous tissue. As the patient grows older the vessels regress and the lesion resembles a simple fibroma. The tumour is of rubbery consistence, and fills the nasopharynx, leading to nasal obstruction; its angiomatous nature may cause severe epistaxis. Although benign, it may expand the face and extend into the orbits, or it may grow into the orifices in the base of the skull, or even erode into the cranial cavity. Deafness may follow blocking of the auditory tube. The tumour occasionally regresses spontaneously in adult life.

Active treatment is by radiotherapy which reduces the vascularity, followed by radical excision, using a transpalatal approach.

MALIGNANT TUMOURS

Malignant tumours of the nasopharynx are usually carcinomata of various types or sarcomata of lymphoid or reticuloendothelial tissue.

Carcinoma

These may be well differentiated squamous neoplasms, but more commonly show a transitional type of epithelium. Differentiation is often poor, and not uncommonly the lesion consists of masses of anaplastic cells very similar to those of a reticulum cell sarcoma. Some tumours, called lymphoepitheliomata, show an intimate mixture of malignant epithelial cells and lymphocytes or lymphoid tissue, and it may be difficult to be sure of the basically carcinomatous nature of the lesion.

Reticuloendothelial neoplasms

Lymphosarcoma and reticulum-cell sarcoma are relatively common in this situation, presumably because of the large amount of lymphoid tissue in the nasopharynx. In addition a soft tissue plasmocytoma is sometimes found; this is histologically similar to the more common plasma cell myeloma of bone marrow (chap. 21) and the patient may eventually develop signs of the disseminated disease. Amyloid deposits are frequently found in this tumour.

Pleomorphic adenoma (mixed tumour)

This tumour is similar to that arising in the salivary glands (p. 19.14), but is usually more aggressive, and tends to recur more consistently. It should therefore usually be regarded as a malignant lesion.

These tumours commonly arise on the lateral wall of the nasopharynx. They present clinically in four ways, (1) nasal obstruction, (2) metastatic deposits in the cervical lymph nodes, especially in the case of carcinoma, (3) involvement of the auditory tube causing deafness and (4) invasion of the base of the skull leading to cranial nerve lesions. Diagnosis is by posterior rhinoscopy, radiographs of the base of the skull, and palpation and inspection of the nasopharynx under general anaesthesia; biopsy is necessary for accurate diagnosis. Treatment is by radiotherapy.

Infection and ulceration of the pharynx

Infection of the pharynx is described on p. 12.18 and other diseases on p. 19.8. Patients are referred to an ENT specialist when there are problems of diagnosis or when complications requiring surgical treatment occur.

In the diagnosis of throat conditions, it is important to examine the nose, nasopharynx and accessory sinuses as well as, in some cases, the larynx and lower respiratory tract. The examination should also include palpation of the cervical lymph nodes and in many cases other superficial lymph nodes. A full blood examination, serological tests and a throat swab are essential. When malignant disease is suspected, biopsy is required; if one tonsil is enlarged without ulceration, tonsillectomy is preferable to a local biopsy. Where an enlarged node in the neck is thought to be malignant, it is important to exclude a

2501199441

Source: https://www.industrydocuments.ucsf.edu/docs/pmbj0000

32.20 *Diseases of the ear, nose and throat*

primary tumour in the upper respiratory and gastro-intestinal tracts before biopsy of the gland is performed.

TONSILLECTOMY

The indications for this operation are recurrent attacks of tonsillitis and persistent tonsillilar infections or cervical adenitis. Enlargement of the tonsils is not an indication for operation unless gross hypertrophy causes choking as soon as the child falls asleep or has difficulty in swallowing. These symptoms are rapidly cured by tonsillectomy. Occasionally patients are referred for tonsillectomy because of recurring upper respiratory tract infections, rheumatism, glomerulonephritis or psoriasis. The tonsils should be removed in these cases only if there is obvious evidence of chronic infection, e.g. redness of the pillars of the fauces, purulent secretion in the crypts or cervical adenitis, not responding to conservative measures.

Contraindications to tonsillectomy are (1) an acute upper respiratory tract infection, (2) an epidemic of poliomyelitis and (3) a history of a bleeding tendency; in the latter case the morbidity caused by recurring infection may justify tonsillectomy after a full haematological examination, provided arrangements for immedate blood transfusion are available.

Type of operation

In adults, tonsils are removed by dissection under general anaesthesia; this permits ligature of the vessels after the tonsils have been removed. The same operation may be done in children, but many doctors favour a guillotine type operation because it can be done more quickly and the postoperative recovery is quick.

Complication of tonsillectomy

The most common and important complication is reactionary haemorrhage within a few hours of operation and it occurs as often after dissection as after the guillotine operation. It may be due to a blood clot in the tonsillar bed not allowing contraction of the vessels. If bleeding does not stop after removal of the clot, no time should be lost in returning the patient to the theatre for ligature of the bleeding point under general anaesthesia. Blood transfusion should be started at the same time, if there is evidence of shock.

Secondary infection is less common and occurs 5–7 days after operation, caused by sloughing of the tonsil bed. It almost invariably responds to rest in bed with antibiotics and sedation. Secondary haemorrhage may be controlled by stitching of the faucial pillars.

Other rare complications are aspiration of blood or a tooth leading to lung collapse or a lung abscess, otitis media and acute torticollis. Earache is present at some stage after every tonsillectomy and may be due to referred pain, but the tympanic membrane should be inspected in every case.

PERITONSILLAR ABSCESS (quinsy)

Peritonsillar cellulitis without pus formation may resolve with antibiotics. Once an abscess has formed, it must be opened. This is done without anaesthesia either by passing a pair of curved forceps through the intratonsillar fossa or by inserting St Clair Thomson forceps directly through the anterior pillar. When the forceps have entered the abscess, the points are separated to widen the opening into the abscess. The opening of a quinsy is momentarily painful, but the subsequent relief is dramatic. The tonsils should be removed when the infection has subsided, as otherwise a recurrence of the quinsy is likely.

DISEASES OF THE LARYNX

Much the most important and common symptom is interference with phonation. This usually takes the form of hoarseness but there may be complete loss of voice. Obstruction of the airway causes dyspnoea, stridor or asphyxia. Cough, haemoptysis and dysphagia are less common symptoms. Pain occurs in deep ulcerative lesion and is referred to the ears; in superficial infections the patient may complain of a raw feeling in the throat.

Methods of examination

This is carried out by indirect laryngoscopy. A large mirror of about 24 mm in diameter is warmed enough to avoid misting. The patient then opens his mouth wide and protrudes the tongue as far as he is able. The tongue is retained in this position by holding it in the left hand with a swab. With illumination from a bull's eye lamp and a forehead mirror, the warmed mirror is passed through the mouth and placed against the soft palate (fig. 32.8). The patient is instructed to breath regularly through the mouth. It is now possible to see the epiglottis, and the posterior part of the inlet of the larynx through the mirror. The patient now says 'ee'; this raises the whole larynx and tilts it forwards allowing inspection of the whole of the interior of the larynx. As the patient breathes in and out, the movements during respiration can be observed, and when he says 'ee' the movements of phonation are seen. It is only by indirect laryngoscopy that the movements of the cords can be demonstrated. This is important in the diagnosis of laryngeal paralysis and in assessing the invasiveness of a tumour. The view obtained by indirect laryngoscopy is a mirror image and, in description, it is important to correct for this (fig. 32.9).

In most cases indirect laryngoscopy can be carried out without anaesthesia, but occasionally spraying of the throat with 10 per cent cocaine is required. It is important

2501199442

Source: https://www.industrydocuments.ucsf.edu/docs/pmbj0000

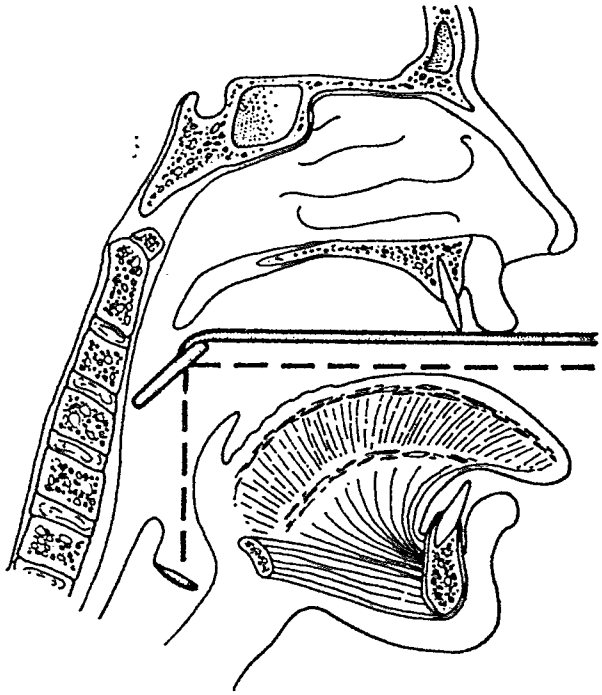

FIG. 32.8. Indirect laryngoscopy.

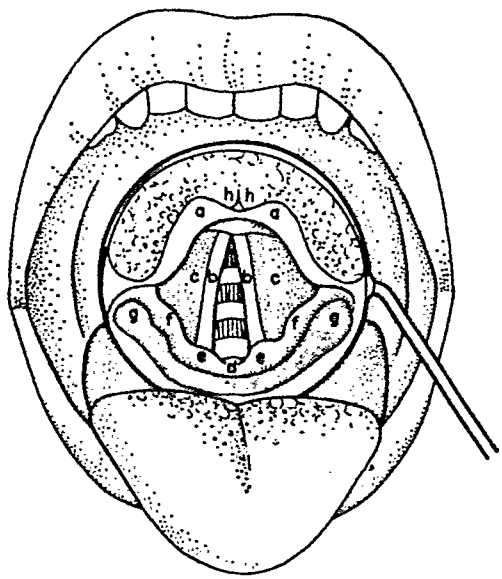

FIG. 32.9. Features of the larynx seen by indirect laryngoscopy. (a) Epiglottis, (b) vocal cord, (c) vestibular cord (false cord), (d) interarytenoid region, (e) corniculate cartilage, (f) cuneiform cartilage, (g) pyriform fossa, (h) vallecula.

that the cocaine should not be swallowed, but spat out into a basin, to avoid absorption of an excessive amount.

If it is not possible to obtain an adequate view of the larynx with the mirror, or if a more detailed inspection is required or if a biopsy is to be performed, direct laryngoscopy, usually under general anaesthesia, is carried out. If malignant disease is suspected, the neck is examined for enlarged lymph nodes, and the larynx palpated for broadening and to exclude fixation to surrounding structures. Other methods of investigation are soft tissue radiography, tomography and contrast radiography.

Acute epiglottitis

Acute epiglottitis is a very dangerous infection of the epiglottis by *H. influenzae* in very young children. The epiglottis may be seen as a bright red cherry-like swelling and it can kill by asphyxia within a few hours. It should be treated with ampicillin; the patient must be closely observed and tracheostomy performed if necessary.

Acute laryngitis

Acute laryngitis is a common complication of acute upper respiratory infections such as coryza, influenza, tonsillitis, sinusitis, etc. It is particularly liable to occur with excessive use of the voice during such infections.

Hoarseness is the main symptom and may vary from slight roughness of the voice to almost complete aphonia. Rawness of the throat may progress to actual pain which is worse on coughing. Swallowing may be painful. The degree of systemic upset depends on the causative condition.

In infancy it often occurs as part of the laryngotracheo bronchitis caused by respiratory syncytial viruses.

On examination, there is diffuse redness of the whole larynx and sticky secretion may be retained on the mucosal surfaces. There may be diffuse swelling of the vocal cords, and slight muscle paresis with bowing of the vocal cords on phonation may be observed. The narrow airway of babies is more easily obstructed and they must be carefully watched for signs such as cyanosis, increasing restlessness, rising pitch of the stridor and costal recession. The patient should be kept in his room and at an even temperature. If there is pyrexia, he should be in bed. Treatment consists of resting the voice. Steam inhalations with menthol are helpful, but critically ill babies are usually nursed in a small clear plastic tent and a mist of water vapour. The causative condition should receive appropriate treatment.

Acute laryngeal stridor

When babies learn to handle and transfer objects to the mouth, acute stridor may result from the inhalation of a foreign body.

Oedema of the glottis

Acute oedema of the larynx most commonly results from infection in the pharynx, e.g. quinsy, or in the neck, e.g. Ludwig's angina. It may also result from (1) trauma, such as a direct injury to the larynx, (2) a scald as when a child drinks a hot fluid, (3) carcinoma of the larynx, (4)

2501199443

Source: https://www.industrydocuments.ucsf.edu/docs/pmbj0000

reaction to radiotherapy, (5) perichondritis due to carcinoma, radiotherapy or rarely tuberculosis or syphilis, (6) hypersensitivity states, e.g. angioneurotic oedema, (7) as part of a generalized oedema, e.g. in glomerulonephritis or heart failure and (8) intrathoracic swellings which obstruct the venous return from the head and neck.

The oedema is mainly confined to the free edge of the epiglottis, aryepiglottic folds and arytenoids, i.e. the laryngeal inlet; the vestibular folds are also involved but the cords and other parts escape. The mucosa is pale in non-inflammatory oedema and red in inflammatory lesions.

TREATMENT

Rest in the upright position in bed is essential. The atmosphere should be humidified by a steam kettle. Ice to suck or cocaine and adrenaline sprays may reduce the oedema. Antihistamines and adrenaline, 0·5–1 ml 1 : 1000 solution by subcutaneous injection, are given in angio-oedema (p. 31.28). The causative condition should be treated. If an adequate airway cannot be maintained by these measures, tracheostomy is required.

Chronic laryngitis

As in acute laryngitis, chronic laryngitis results from excessive use of the voice, particularly in the presence of infection of the teeth, tonsils or sinuses, exposure to atmospheres containing excessive dust, fumes, humidity or dryness, and excessive smoking. It is a frequent accompaniment of chronic bronchitis.

Hoarseness is the main symptom and is often worse in the morning. There may be a constant desire to clear the throat and this irritable cough may produce pellets of mucus.

On laryngoscopy there is redness, most marked on the vocal cords and vestibular folds, and oedema may develop. The cords and false cords frequently hypertrophy and the swelling is usually smooth and regular, but occasionally nodular, when it may be difficult to distinguish the appearances from a carcinoma.

TREATMENT

At first, voice rest and the use of oil of pine steam inhalation should be combined with eradication of any sepsis.

Once the voice has improved, overuse of the voice should be avoided and speech therapy may be required to correct faulty voice production. Bad atmospheric working conditions should be avoided. In resistant cases it may be necessary to strip oedematous portions of mucosa under direct laryngoscopy. It cannot be emphasized too strongly that no case of hoarseness should be treated as laryngitis for longer than three weeks without an adequate inspection of the vocal cords. An early carcinoma of the vocal cord, where the prognosis is good, may be missed in this way and the opportunity of treatment with good prognosis lost.

Tuberculous laryngitis

This was once a common complication of pulmonary tuberculosis, but rarely occurs in patients treated with antibiotics. It may also occur in acute miliary tuberculosis and as a sequela of lupus of the face, nose and pharynx. The voice is weak and hollow, and there may be pain on speaking or swallowing fluids. Laryngoscopy may show characteristic infiltration of the arytenoids and tuberculous ulcers of the vocal cords.

In any chronic case of laryngitis, it is important to suspect the possibility of tuberculosis and to examine the sputum and radiographs of the chest. Sometimes a biopsy is required.

Syphilitic laryngitis

Syphilitic infection of the larynx is now rare in Britain. Formerly laryngitis was common in the untreated secondary stage and also occurred in congenital infection and the tertiary stage of acquired disease. Gummata may be difficult to distinguish from malignant disease and biopsy may be required in addition to serological tests for syphilis (p. 13.7).

Laryngeal polyp

A polyp, usually seen at the junction of the anterior and middle thirds of one vocal cord, may result from organization of a small haematoma, due to voice strain, often during a laryngeal infection. It causes hoarseness. In early cases resolution may occur with voice rest, but once there is organization, removal under direct laryngoscopy is required.

Vocal nodules

These are called singer's nodes because they are seen in singers, particularly sopranos and tenors, but they also occur in others who use their voices excessively, with faulty voice production. Initially the voice loses its quality and later becomes hoarse. On examination, a white smooth elevation is seen at the junction of the anterior and middle thirds of one or both vocal cords. When very small, resolution may occur with prolonged voice rest, but in most cases surgical removal is required. This should be done under direct laryngoscopy using an operating microscope so that the removal can be precise, avoiding damage to normal structures. Aftercare is important, and voice abuse should be avoided; speech therapy or retraining of the singing voice may be necessary.

Keratosis of the larynx

In keratosis or leucoplakia, white raised patches occur on the vocal cords. It has been suggested that the

2501199444

Source: https://www.industrydocuments.ucsf.edu/docs/pmbj0000

PRIVILEGED & CONFIDENTIAL

condition is commonest in those subject to recurring laryngitis, and it is important because in some cases it is premalignant.

The main symptom is hoarseness and, on examining the larynx, the white patches are seen. Biopsy is needed to confirm the diagnosis and to exclude malignancy. The patient should be kept under prolonged supervision and, if there is a change in the voice or extension of the lesions, a further biopsy is required.

Laryngeal paralysis

AETIOLOGY

All the muscles of the larynx are supplied by the recurrent laryngeal nerve with the exception of the cricothyroid muscle; this is supplied by the external laryngeal nerve, a branch of the vagus. Laryngeal paralysis may result from lesions involving the vagus in the medulla, e.g. vascular lesions, syringomyelia, tumours, motor neurone disease and poliomyelitis. The vagus nerve may also be involved as it passes to the jugular foramen, e.g. by an acoustic neuroma, carcinoma of the nasopharynx, basal meningitis or fracture of the base of the skull. High in the neck, the vagus nerve may be damaged by trauma or by involvement in inflammatory or malignant disease, particularly of lymph nodes. The left recurrent laryngeal nerve passes further down into the superior mediastinum than the right and is particularly likely to be involved in carcinoma of the lung or a mediastinal metastasis from such a tumour. Other causes of paralysis in the mediastinum are, on the left side, aneurysm of the aorta, carcinoma of the thoracic oesophagus, mediastinal masses, e.g. lymphosarcoma, lymphadenoma or secondary breast tumour, and tuberculosis of the cervical pleura; and on the right side, aneurysm of the subclavian or innominate arteries, carcinoma of the apex of the right lung, tuberculosis of cervical pleura. In the neck the recurrent laryngeal nerves are liable to damage as they pass in the groove between the trachea and oseophagus from diseases of or surgery to the thyroid gland, carcinoma of the cervical oesophagus and from malignant disease involving cervical lymph nodes.

CLINICAL FEATURES

Semon's Law states that in incomplete paralysis of the vocal cord, the function of the adductor muscles only is retained and the cord lies adducted to the midline position. In complete paralysis, the cord lies midway between full abduction and adduction as it does after death. From this the effect of paralysis can be predicted.

In unilateral incomplete paralysis, e.g. after trauma during thyroidectomy, the affected cord lies in the midline. There may be very transient hoarseness, but often the voice is normal because the normal cord can adduct to the fixed cord in phonation. It can also abduct sufficiently to give a good airway.

In unilateral complete paralysis as in carcinoma of the lung, the affected cord is in the cadaveric position. The normal cord does not meet the affected cord on phonation and only a whisper with a great deal of air escape is possible. A normal explosive cough is not possible and a cough is ineffective. The airway is quite free. If the patient survives long enough, the normal cord compensates by moving across the midline to meet the affected cord with improvement in the voice. In bilateral incomplete paralysis, e.g. after thyroid surgery, both vocal cords are adducted to or near to the midline. This interferes with respiration and tracheostomy may be required. In other cases respiratory embarrassment may only occur on moderate exertion. The voice is good and strong; if a tracheostomy is done a flap valve allows inspiration through the tube and expiration through the cords. If improvement does not occur after 6 months, an operation may be done to displace the more affected cord laterally. This improves the airway at the expense of the strength of the voice, but this may be accepted by a young woman so that she can dispense with a tracheostomy.

In bilateral complete paralysis, e.g. after a brainstem vascular lesion, both vocal cords lie in the cadaveric position. The airway is good but the cough is ineffective and the lower respiratory tract has lost its upper sphincter. Because both vagus nerves or nuclei are affected there is often loss of sensation in the larynx; this aggravates the risk of aspiration of food and saliva. The voice is very poor. The prognosis is usually grave, but in non-progressive lesions, aspiration may be minimized by tube feeding and tracheostomy may also be required.

FUNCTIONAL APHONIA

Unlike organic lesions a functional disorder produces paralysis of the adductors of both vocal cords during phonation. This occurs mainly in young women during emotional stress. The voice may be lost completely or more often reduced to a whisper; the voice is usually lost suddenly and also recovers suddenly. Although the cords fail to adduct on phonation, they do so on coughing. The patient may not speak but she can be heard to cough. On laryngoscopy the cords will be seen to adduct on coughing but not on phonation. The most satisfactory treatment is speech therapy.

Tumours of the larynx

BENIGN TUMOURS

Papillomata occur singly on the vocal cord in adults and give rise to hoarseness; they are removed by direct laryngoscopy. Multiple papillomata occur in infants and small children. They are seen on the cords and vestibular folds but may extend to the epiglottis or to the trachea

2501199445

Source: https://www.industrydocuments.ucsf.edu/docs/pmbj0000

and bronchi. The papillomata interfere with phonation and with the airway, and treatment consists of endoscopic removal with care to avoid damaging the underlying structures. This requires to be done repeatedly until puberty when the condition tends to clear up. In some cases tracheostomy is required to maintain the airway.

Chondroma, angioma, lipoma, rhabdo- and leiomyoma and neurofibroma also occur rarely in the larynx.

MALIGNANT TUMOURS

Although adenocarcinoma, basal cell carcinoma and sarcoma occur, most malignant tumours of the larynx are squamous cell carcinomata, ranging from well differentiated highly keratinized tumours to anaplastic tumours.

The commonest site is the anterior half of one vocal cord, i.e. the glottic carcinoma. When a tumour arises in the larynx above the vocal cords it is known as supraglottic, if below the cords, subglottic.

It is fortunate that glottic carcinoma is the commonest type, because, if it is diagnosed early, the prognosis is excellent. Approximately 80 per cent of early glottic cancers are cured by treatment. As the growth is on the free edge of the cord, hoarseness occurs early and may be the only symptom. Persistent hoarseness should never be neglected and labelled 'laryngitis'. If it lasts for more than 3 weeks, the vocal cords should be seen by either indirect or direct laryngoscopy. While a carcinoma of the vocal cord is confined to the anterior half of the cord and does not extend anteriorly to the anterior commissure, posteriorly to the arytenoid or laterally into the muscle, there is little tendency to metastasize to regional lymph nodes. Once it has spread beyond these limits, the deep cervical lymph nodes are usually soon involved. An anterior growth may spread first to the prelaryngeal node overlying the coricothyroid membrane. On indirect laryngoscopy a carcinoma is seen as an irregular thickening of the vocal cord which may appear grey. Tumours in other sites in the larynx may be more papillary or have the appearance of a malignant ulcer. In late cases there may be broadening of the laryngeal skeleton, fixation of the larynx to the prevertebral fascia, or invôlvement of the regional nodes. Distant metastases occur only rarely.

TREATMENT

The usual treatment in all sites is radiotherapy but a few surgeons select some cases for primary surgical excision. If there is a failure to respond to radiotherapy or if there is recurrence of tumour after an initial response, total laryngectomy is usually required. In this operation the whole larynx including the laryngeal cartilages and hyoid bone together with the upper segment of the trachea are excised. The anterior wall of the pharynx is repaired to restore the food channel and the lower cut end of the trachea is brought out into the neck as a terminal tracheostomy. Most of these patients learn to speak using an oesophageal voice, i.e. air is swallowed into the oesophagus and regurgitated to vibrate the pharyngeal sphincter, which replaces the vibrations of the vocal cords.

Swellings in the neck

Swellings in the neck present a common diagnostic problem and are conveniently considered here. They may lie laterally or in the midline.

LATERAL SWELLINGS

Lymph nodes

The cervical lymph nodes may be enlarged in tuberculosis, in the reticuloses, by secondary carcinoma spreading from the lip or tongue, thyroid, pharynx, larynx or lung, and by ascending spread from a breast carcinoma or, on the left side of the neck, from the stomach and pancreas via the thoracic duct.

In tuberculosis the nodes are characteristically matted together; they are firm at first, but soften as they become caseous. Various groups of nodes may be affected in turn; most commonly the upper deep cervical nodes, particularly the tonsillar gland or jugulodigastric node are involved, and by extension the lower deep cervical nodes in relationship to the jugular vein. In previous years many patients developed multiple cervical scars and sinuses, often disfiguring ones, resulting from the drainage of tuberculous abscesses or from radical surgery for the excision of tuberculous nodes and sinuses in the neck. Since tuberculosis is less frequent nowadays, such lesions are rarely seen in Britain (p. 14.9).

Today, the commonest cause of lymph node swelling of the neck in young adult patients in Britain is infectious mononucleosis. Less common is lymphoreticulosis; such nodes have a rubbery feel, are separable into discrete masses and attain a large size painlessly in the short space of a few months. Many of these patients are found to have other masses of enlarged lymph nodes in the chest and abdomen, and splenomegaly.

In enlargement of lymph nodes secondary to malignancy of the upper oesophagus and larynx, bronchus and breast, the affected nodes are usually matted together as one fixed mass and stony hard. The group of nodes involved is usually closely related to the primary neoplasm, but malignant cells may on occasion spare the nearest group to involve one more remote.

The cervical lymph node enlargement from a secondary carcinoma of the thyroid gland may be the presenting feature of this disease; this is not uncommon in the papillary type of thyroid carcinoma, and the lymph node lesion has been known as a lateral aberrant thyroid.

2501199446

Source: https://www.industrydocuments.ucsf.edu/docs/pmbj0000

Branchial cyst

This owes its origin to a congenital defect in the formation of the cervical sinus (vol. 1, p. 18.34). It develops when the second branchial arch overgrows to meet the fifth and the cervical sinus formed as a depression exterior to the primitive pharyngeal region, in the floor of which lie the third and fourth arches. This sinus customarily closes, but should it persist it forms a branchial cyst. This potential space does not become apparent clinically until early adult life when the patient, usually a young woman, presents with a swelling in the upper neck at or near the angle of the jaw. The swelling is usually fluctuant and transilluminates; it is initially painless. However, it may become inflamed, tender and painful. The cyst is usually lined partly by squamous epithelium and partly by ciliated columnar epithelium. Characteristically there is abundant lymphoid tissue deep to the epithelium. The cyst is easily excised with lasting cure, provided all the branchial tissue is removed.

Should the second arch fail to fuse with the fifth, an opening remains in the neck, usually related to the anterior border of the sternomastoid. A fistulous track, **a branchial fistula**, leads between the main arches of the neck to the pharynx near the tonsil, which region represents the territory of the second branchial pouch (vol. 1, p. 18.35). Excision is also indicated.

Cystic hygroma

This also presents as a fluctuant swelling in the neck; it is common in children, and occurs in the posterolateral part of the neck, often extending indeed into the suprascapular area (p. 17.35).

Goitre

A goitre may extend into the lateral part of the neck. Asymmetrical nodules of the thyroid gland present in one lobe are usually easily recognized as part of the main thyroid gland. Diffuse enlargement of the thyroid gland is recognized by its characteristic upward and downward movement on swallowing.

Rarer causes

These include aneurysmal dilation of the carotid vessels, with accompanying expansile pulsation, and carotid body tumours which present as firm swellings; they may transmit the carotid pulsation and give an erroneous clinical impression of aneurysm.

MIDLINE SWELLINGS

The commonest midline swelling is an enlarged thyroid or goitre. Rarer causes are dermoid cyst (vol. 2, p. 28.5), effusion into a subhyoid bursa, enlargement of the lymph nodes in the suprasternal space, the appearance at this site of expanding intrathoracic aortic aneurysm, and a thyroglossal cyst.

Thyroglossal cysts arise in the thyroglossal duct, which is the original outgrowth of primitive embryonic thyroid tissue from the thyroid bud posterior to the tuberculum impar at the junction of the anterior and posterior thirds of the embryonic tongue (vol. 1, pp. 18, 30, 34). The duct extends downwards into the neck as a column of cells, and the mature thyroid gland is derived from this. A thyroglossal cyst results from the persistence of this duct, and may arise anywhere in the midline from the posterior third of the tongue in the line of the thyroglossal duct to the pyramidal lobe of the thyroid gland (vol. 1, fig. 18.57). The cyst has an epithelial lining which may be squamous or ciliated columnar, or a mixture of the two, and foci of thyroid glandular tissue may be seen in its wall. Like a branchial cyst, a thyroglossal cyst may become inflamed and the skin over it may break down and form a fistula. The skin at the site of a recent fistula is often puckered. Some thyroglossal cysts extend behind the hyoid bone and the track of the thyroglossal duct may loop up and over it before reaching the base of the tongue. For this reason the cyst, the entire track and the central portion of the hyoid are usually excised in one piece.

FURTHER READING

BALLANTYNE J. (1970) *Deafness*, 2nd Edition. Edinburgh: Churchill Livingstone.

SCOTT-BROWN W.G., BALLANTYNE J. & GROVES J. (1971) *Diseases of the Ear, Nose and Throat*, 3rd Edition. London: Butterworth.

FRIEDMANN I. (1973) *Pathology of the Ear*. Oxford: Blackwell Scientific Publications.

MAWSON S.R. (1967) *Diseases of the Ear*, 2nd Edition. London: Edward Arnold.

RANSOME J., HOLDEN H.B. & BULL T.R., eds. (1972) *Recent Advances in Otolaryngology*, 4th Edition. Edinburgh: Churchill Livingstone.

SIMPSON J.F., *et al.*, eds. (1967) *Synopsis of Otolaryngology*, 2nd Edition. Bristol: Wright.

STEWART J.P. (1968) *Logan Turner's Diseases of the Nose, Throat and Ear*. Bristol: Wright.

WILSON T.G. (1962) *Diseases of the Ear, Nose and Throat in Children*, 2nd Edition. London: Heinemann Medical.

2501199447

Source: https://www.industrydocuments.ucsf.edu/docs/pmbj0000